

Rare Acromial Non-Union that was Managed Conservatively with Good Outcomes: A Case Report

Makgabo J Tladi*

Surgeon, Louis Pasture Hospital, Suite 44 Louis Pasture Hospital Pretoria, South Africa

Article Info

***Corresponding author:**

Makgabo J. Tladi

Surgeon

Louis Pasture Hospital Pretoria

South Africa

Tel: +27 83 529 7395

E-mail: mjtlati.ortho@gmail.com

Received: October 1, 2018

Accepted: October 8, 2018

Published: October 12, 2018

Citation: Tladi MJ. Rare Acromial Non-Union that was Managed Conservatively with Good Outcomes: A Case Report. *Madridge J Case Rep Stud.* 2018; 2(2): 85-87.
doi: 10.18689/mjcrs-1000121

Copyright: © 2018 The Author(s). This work is licensed under a Creative Commons Attribution 4.0 International License, which permits unrestricted use, distribution, and reproduction in any medium, provided the original work is properly cited.

Published by Madridge Publishers

Abstract

This case report describes a rare acromial non-union that developed after the fracture was initially missed. The patient had good outcomes following conservative management. An acromial fracture should be part of a differential diagnosis of traumatic shoulder pain.

Keywords: Acromion; Non-union; Os acromiale; Scapular fracture.

Introduction

Scapular fractures are very rare, accounting for only 1% of all fractures, and are associated with high energy [1]. A scapular fracture can be missed during initial patient evaluation, leading to pseudo-arthrosis [2]. This is a case report of an acromial non-union that was initially missed. We could not find a case of non-union of the acromion that was managed conservatively following direct trauma.

Case Report

A 35-year-old male patient presented with right-shoulder pain. He reported that 2 years previously he had been involved in a motor vehicle accident as a driver and that he had informed his treating doctors about shoulder pain. Shoulder X-rays were done and he was informed that they were normal. He also sustained a left femur fracture that was managed surgically. His current pain was worsened by lifting heavy weights. He had no limitation with above-head activities. He was left-hand dominant.

The shoulder examination revealed mild shoulder tenderness with negative signs of impingement or rotator cuff pathology. His constant shoulder score was 92. The shoulder X-ray showed non-union of the acromion with irregularity between fragments (Figures 1a and 1b). The ultrasound did not report bursitis or rotator cuff pathology.

He was given nonsteroidal anti-inflammatory drugs to manage his pain as well as physiotherapy. He came back after six weeks and reported that his pain had improved. At 3 months, he was pain-free and not taking any analgesia. He remains pain-free to date.

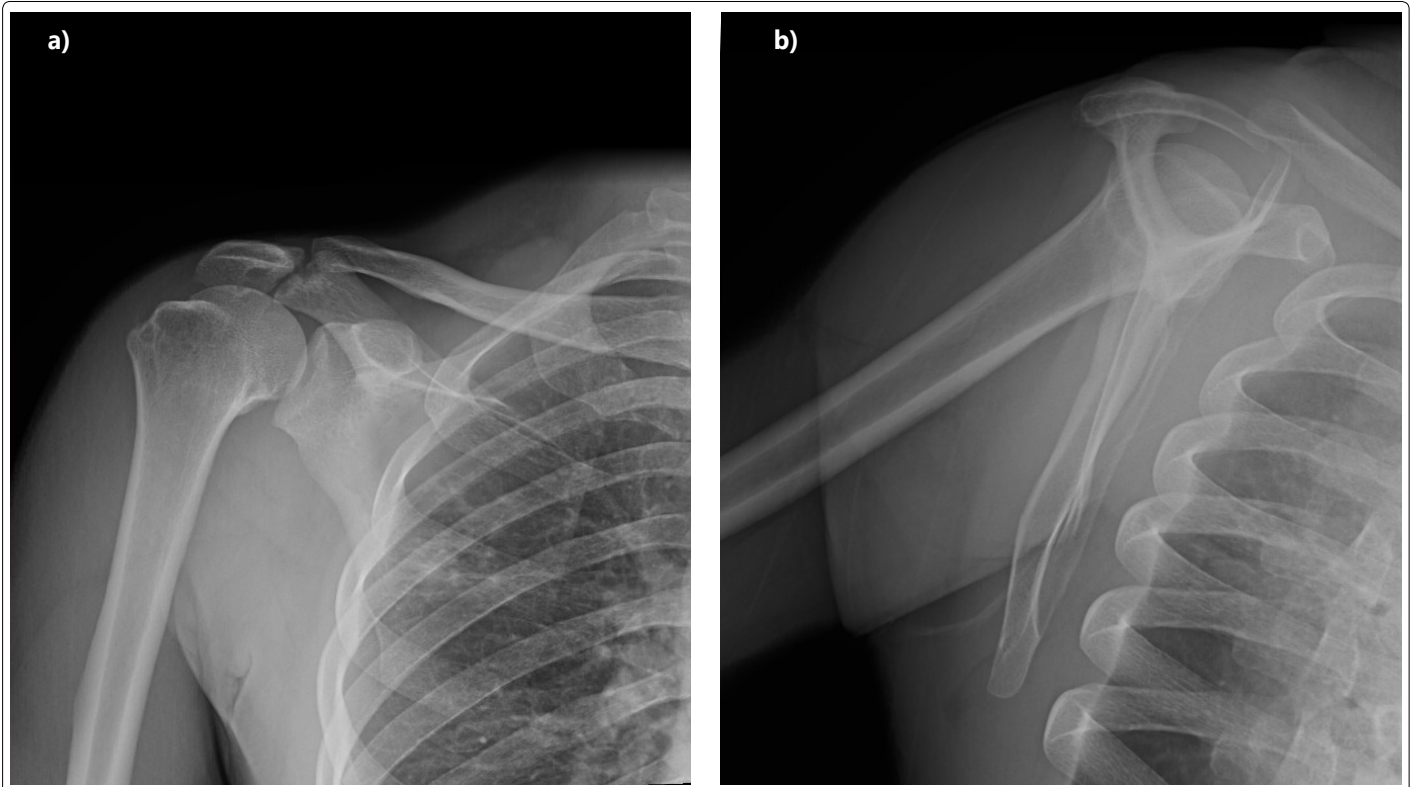


Figure 1(a,b): Shoulder X-ray showing non-union of the acromion with irregularity between fragments

Discussion

Fractures of the acromion are reported to be rare injuries [1]. These fractures can be associated with other shoulder injuries, which include fracture of the scapula, clavicle, and coracoid process. Failure to protect an undisplaced acromial fracture could lead to a non-union that may progress to warrant surgical management [3].

Although the fracture can be diagnosed using X-rays, Lee et al. [4] reported that an ultrasound can assist with diagnosing avulsion fracture of the acromion. We recommend that if one is in doubt, a shoulder CT scan can help with the diagnosis.

The non-union of the acromion that we could find through a literature search is the type that occurred iatrogenically after the standard acromioplasty. The fracture was initially missed by the chief surgeon who performed the procedure. The patient's pain improved over 18 months of conservative management [5].

The diagnosis of os acromiale should be considered. This condition results from failure of the acromial process to fuse and is commonly asymptomatic. It may present with signs and symptoms of impingement. There are three types, which include pre-acromion, meta-acromion or mesa-acromion, with the latter being the common type. Failure to recognise os acromiale can result in unsuccessful acromioplasty. Symptomatic os acromiale can be managed with bone graft and fixation [6,7]. The diagnosis of os acromiale can be confused with acute fracture.

Copuroglu et al. reported pseudo-arthritis of the scapula spine that was missed two years after the patient had been involved in the motor vehicle accident. The patient presented

with pain and was managed surgically with good outcomes [2]. This case is similar to our case due to its duration and missed diagnosis. As-Sultany et al. also reported a good patient outcome following a scapular spine fracture [8].

Anavian et al. [9] reported good outcomes of acromion and coracoid process fractures following surgical intervention. The surgical indications are: 1 mm fracture displacement, disruption of superior suspensory complex, painful non-union, and concomitant ipsilateral operation of the scapular fracture [9]. Surgical management for an acute fracture includes open reduction and internal fixation using either K-wires, screws, and plates and screws [9,10]. Implants may be removed due to irritation of the tissues.

We think the patient did not want surgical intervention because it was a less dominant limb and his pain had responded to the analgesia that was given to him; the fibrous tissue between the fragments might have been stable. It is important for one to have a differential diagnosis of acromial fractures during initial evaluation of a patient with shoulder pain.

Conclusion

The acromial fracture can be missed during initial evaluation. One should have an index of suspicion with shoulder pain after high-energy trauma. If a diagnosis of acromial non-union has been made the patient should be monitored for impingement.

Conflicts of Interest

The author declares no conflict of interest.

References

1. Koval KJ, Zuckerman JD, Rockwood CA. Scapula. Handbook of fractures. Philadelphia: Lippincott Williams & Wilkins; 2002; 75-79.
2. Copuroglu C, Tan L, Copuroglu E, Ciftdemir M, Ozcan M. Pseudo-arthritis of the scapula: a case report with a delayed diagnosis. *Strategies Trauma Limb Reconstr.* 2014; 9(3): 173-177. doi: 10.1007/s11751-014-0210-2
3. Gorczyca JT, Davis RT, Hartford JM, Brindle TJ. Open reduction internal fixation after displacement of a previously non-displaced acromial fracture in a multiply injured patient: case report and review of literature. *J Orthop Trauma.* 2001; 15(5): 369-373.
4. Lee CH, Choi YA, Lee SU. Ultrasonographic diagnosis of non-displaced avulsion fracture of the acromion: a case report. *Ann Rehabil Med.* 2015; 39(3): 473-476. doi: 10.5535/arm.2015.39.3.473
5. Marr DC, Misamore GW. Acromion nonunion after anterior acromioplasty: A case report. *J Shoulder Elbow Surg.* 1992; 1(6): 317-320. doi: 10.1016/S1058-2746(09)80059-1
6. Barbier O, Block D, Dezaly, Sirveaux F, Mole D. Os acromiale, a cause of shoulder pain, not to be overlooked. *Orthop Traumatol Surg Res.* 2013; 99(4): 465-472. doi: 10.1016/j.otsr.2012.10.020
7. Pogorzelski J, Hussain ZB, Lebus GF, Fritz EM, Millett PJ. Anterior Capsular Reconstruction for Irreparable Subscapularis Tears. *Arthrosc Tech.* 2017; 6(4): e951-e958. doi: 10.1016/j.eats.2017.03.008
8. As-Sultany M, Tambe A, Clark DI. Nonunion of a scapular spine fracture: Case report and management with open reduction, internal fixation and bone graft. *Int J Shoulder Surg.* 2008; 2(3): 64-67. doi: 10.4103/0973-6042.42202
9. Anavian J, Wijdicks CA, Schroder LK, Vang S, Cole PA. Surgery for scapula process fractures: good outcomes in 26 patients. *Acta Orthop.* 2009; 80(3): 344-50. doi: 10.3109/17453670903025394
10. Mehdi Nasab SA. Isolated displaced fracture of the acromion: a rare case report and the consequence of treatment by open reduction and pin fixation. *Arch Trauma Res.* 2013; 1(4): 184-186. doi: 10.5812/at.8762