

Parietization of Colon following Tuberculous Acites

Shailesh Kumar*, Abu Masud Ansari and Devaa Dutta Poddar
PGIMER Dr RML Hospital, India

A 46 years old menopausal female presented to Surgical OPD with the complaints of recurrent pain abdomen with vomiting and fever off and on. Pt was a treated case of Koch's abdomen. There was no history of jaundice and other co- morbidities.

On examinations, she had tenderness in Right Hypochondrium (RHC) on deep palpation. Rest of the Parameters were normal.

On Investigation, ultrasonography of abdomen revealed multiple Gallstones with Normal CBD. Rest of the abdomen and pelvis were normal. Her blood and urinary examinations were within normal limits. X-ray chest revealed features suggestive of healed tuberculosis.

Pt was posted for Laparoscopic Cholecystectomy. After pneumo-peritoneum, 10mm Optical port was placed in periumbilical area. On diagnostic laparoscopy, whole of the colon was densely adhered to the pariety (Fig-1a). Liver, Gall bladder and Spleen were nor not visible. As Falciform Ligament and liver was not visible, two working port were inserted in the mid clavicular line both side around 3 inches below the Costal Margin in an anticipation to de-Parietization of the transverse colon to assess the feasibility to proceed. We broke the adhesion between the transverse colon and pariety in the midline and proceeded to de-parietisation the whole transverse colon with the help of ultrasonic scissor (Fig-1b). After that we could visualised the Liver and Gall bladder (Fig-1c) and proceeded with the Laparoscopic Cholecystectomy.

Abdominal cavity is the sixth most common extra peritoneal site of tuberculosis¹. There are different studies that support the crucial role of diagnostic laparoscopy in the diagnosis of abdominal tuberculosis. The diagnostic laparoscopy revealed ascetic fluid, violin string adhesion of peritoneum and omental thickness². Peritoneal involvement is a common features and more than half of the patients presents with ascites, Lymphadenopathy and stranding of the mesenteric fat³.

Laparoscopy is normally accepted as accurate and prompt diagnostic tools in case of suspected abdominal tuberculosis.

Keywords: Koch's Abdomen, Parietization, Colon, Laparoscopy.

References:

1. Sharma MP, Bhatia V, Abdominal Tuberculosis. Indian J Med Res 2004; 120:305-315 [PubMed]
2. D Mistikas, T Kapp and Montmollin de. Laparoscopic diagnosis of abdominal tuberculosis. HippoKratia. 2016 Ap-jan; 20(2):175.
3. Sinant T, Sheikh M, Ramadan S, Sahnwey S, Behbehani A. CT- features in abdominal Tuberculosis: 20 years Experience.BMC Medical imaging. 2002; 2 [PMC free article][PubMed]

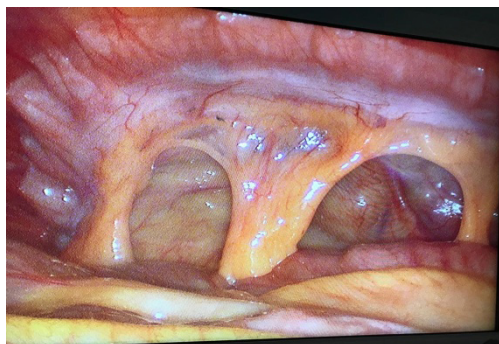


Fig-1a (Parietization of colon)

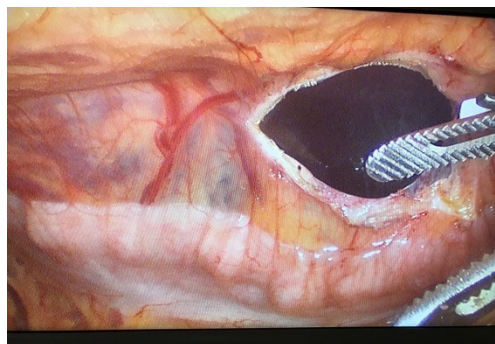


Fig-1b (De-parietization of Colon)

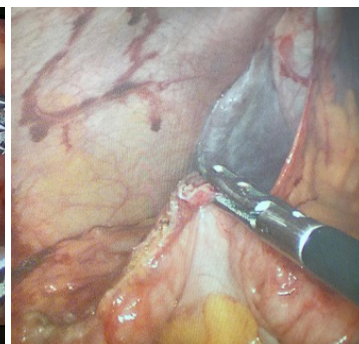


Fig-1c (Visualisation of Liver & Gall Bladder)