

Nevus of Ota

El Jouari O*, Senhaji G, Elloudi S, Baybay H and Mernissi FZ

Department of Dermatology, University Hospital, Hassan II, Fez, Morocco

Article Info

***Corresponding author:**

EL Jouari Ouiame

Department of Dermatology
University Hospital, Hassan II
Fez
Morocco
E-mail: eljouariouiame@gmail.Com

Received: August 29, 2018

Accepted: September 24, 2018

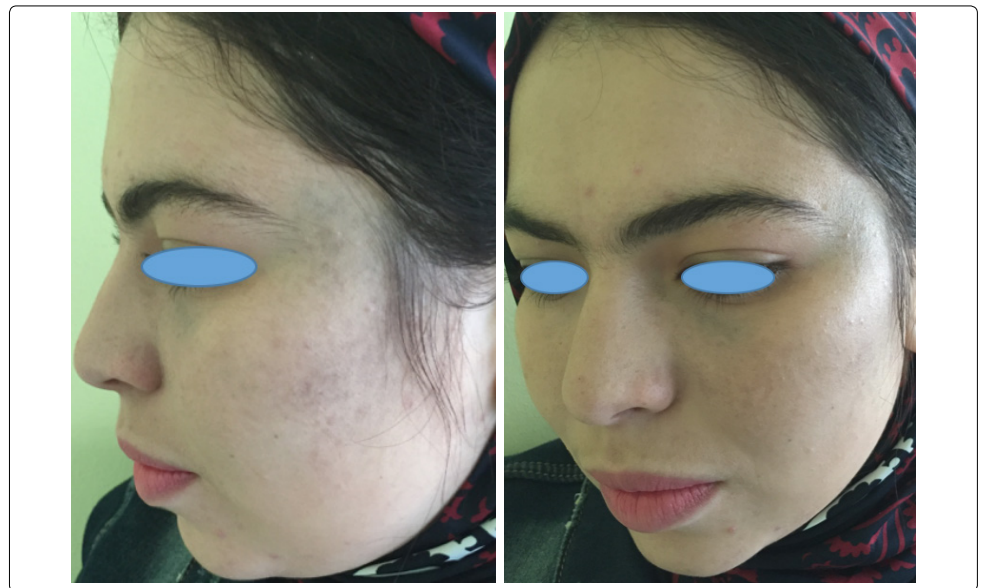
Published: September 28, 2018

Citation: El Jouari O, Senhaji G, Elloudi S, Baybay H, Mernissi FZ. Nevus of Ota. *Madridge J Dermatol Res.* 2018; 3(2): 77-78. doi: 10.18689/mjdr-1000118

Copyright: © 2018 The Author(s). This work is licensed under a Creative Commons Attribution 4.0 International License, which permits unrestricted use, distribution, and reproduction in any medium, provided the original work is properly cited.

Published by Madridge Publishers

A 32 year old women has had, since birth, pigmented spots of the left periorbital area without involving the sclera [Figure 1, 2].



Figures 1-2. blue brown infracentimetric patches sitting in left periorbital.

There has been no change in the extent of the lesion. The patient noticed that the spots become sometimes some what darker. Dermoscopy revealed multiples brown areas without structures [Figure 3].

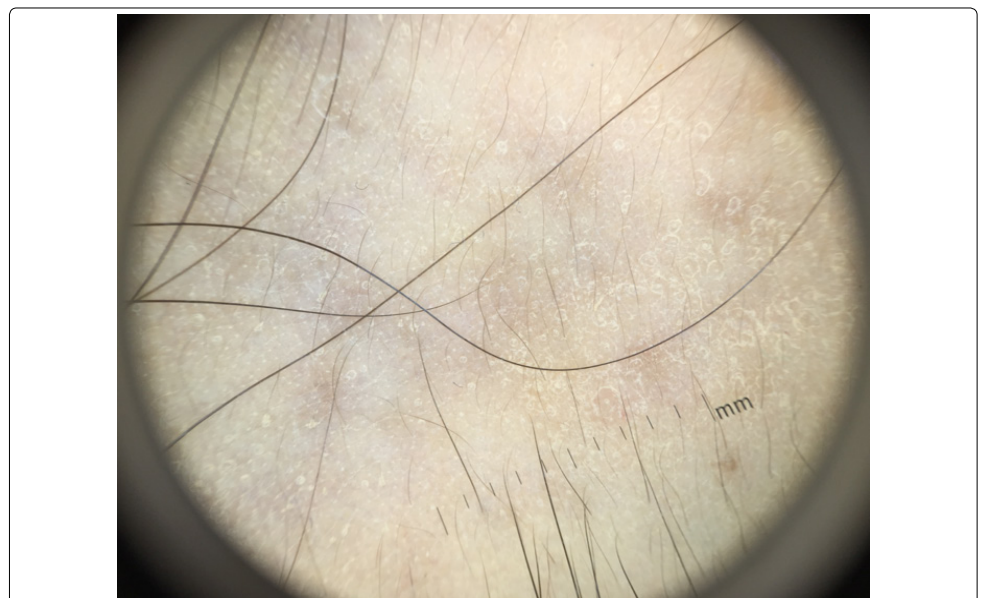


Figure 3. multiples brown areas without structures.

Ota is a congenital pigmentary disorder of the skin and mucous membranes, observed frequently in the yellow race and blacks [1]. It is a macular discoloration of the middle and upper portions of the face with common involvement of the periorbital area [2]. Most cases are sporadic, rare family clusters have been reported [3] and are characterized as being unilateral (95%, having a female predilection (80%, displaying scleral lesions (65%), and being congenital (60%) [2]. The lesions were composed of brown and blue macules the size of which varied from that of a grain of rice to that of lentil. The overall pigment picture varied from deep purplish-blue to light brownish-blue [1]. Lesions tend to be slate-gray to brown in color with a 'powder-blast burn' appearance. The forehead, temple, periorbital area, cheek, and nose are commonly involved. Rarely, pigmentation is bilateral and large areas of the face and oral mucous membranes are affected [3]. The nevus of Ota is a misnomer because it does not contain true nevus cells and derives its pigmentation from dendritic melanocytes which are found in the reticular layer of the dermis [2]. The treatment options for this condition included cryotherapy, dermabrasion, surgical excision and cosmetic camouflage. Although The Q-switched lasers have been used successfully to treat nevus of Ota [4].

Conflict of Interest

The authors declare no conflicts of interest.

References

1. Mishima Y, Mevorah B. Nevus Ota and Nevus Ito in American Negroes. *Journal of Investigative Dermatology*. 1961; 36(2): 133-154.
2. Page DG, Svirsky JA, Kaugars GE. Nevus of Ota with associated palatal involvement. *Oral Surg Oral Med Oral Pathol*. 1985; 59(3): 282-284.
3. Elouarradi H, et al. Mélanocytoseo culopalpébrale ou naevus d'Ota. *Pan African Medical Journal*. 2014; 17:231. doi:10.11604/pamj.2014.17.231.3540
4. Aurangabadkar S. QYAG5 Q-switched Nd:YAG Laser Treatment of Nevus of Ota: An Indian Study of 50 Patients. *J Cutan Aesthet Surg*. 2008; 1(2): 80-84. doi: 10.4103/0974-2077.44164